

## Case Report

## Alveolar Echinococcosis Located in the Liver: Report of a Case

 Mehmet Sait Ozsoy<sup>1</sup>,  Fatih Buyuker<sup>1</sup>,  Hakan Baysal<sup>1</sup>,  Orhan Alimoglu<sup>2</sup>

<sup>1</sup>Istanbul Medeniyet University, Goztepe Prof. Dr. Suleyman Yalcin City Hospital, The Clinic of General Surgery, Istanbul, Turkey,

<sup>2</sup>Istanbul Medeniyet University, Goztepe Prof. Dr. Suleyman Yalcin City Hospital, The Department of General Surgery, Istanbul, Turkey

### ARTICLE INFO

Received: Feb 22, 2022  
Accepted: Apr 16, 2022  
Available online: May 20, 2022

### CORRESPONDING AUTHOR

Mehmet Sait Ozsoy, Istanbul Medeniyet University, Goztepe Prof. Dr. Suleyman Yalcin City Hospital, Clinic of General Surgery  
E-mail: [saitozsoy@gmail.com](mailto:saitozsoy@gmail.com)  
Phone Mobile: +90 532 598 83 83

### CITATION

Ozsoy MS, Buyuker F, Baysal H, Alimoglu O. Alveolar Echinococcosis Located in the Liver: Report of a Case. International Journal of Echinococcoses 2022;1(2):46-8. DOI: 10.5455/IJE.2022.02.02

The journal is the official publication of The Turkish Association of Hydatidology

Copyright@Author(s) - Available online at [www.echinococcoses.org](http://www.echinococcoses.org)  
Content of this journal is licensed under a Creative Commons Attribution-NonCommercial 4.0 International License.



### ABSTRACT

Echinococcosis is a parasitic infection caused by larval and cyst stages of *Echinococcus granulosus* living in dogs in humans. The definitive host of the parasite is dog, intermediate hosts are sheep, cattle and humans. The causative pathogen is mostly *Echinococcus granulosus*. *Echinococcus multilocularis* (alveolaris) and other agents are less common. Only 3% of hepatic hydatid cysts are alveolar hydatid cysts. In this study, we aimed to present a case of Alveolar echinococcosis located in the right lobe of the liver due to *Echinococcus alveolaris*, together with the operation images.

We evaluated the preoperative, peroperative and postoperative course of a patient who was examined with abdominal pain in our clinic and in radiological and serological examinations, we found an alveolar hydatid cyst located in the liver and underwent surgery.

Our patient was a 31-year-old female. She applied for abdominal pain. Ultrasonography revealed a cystic mass of approximately 17 cm in diameter in the right lobe of the liver. In laboratory examinations, the hydatid hemagglutination test was positive at a titer of 1/2560. Hematological and biochemical parameters were normal. MRI showed a 171\*125 mm sized, lobulated, locally calcified cystic mass in the right lobe of the liver. After evaluating the relationship of the lesion defined in CT angiography imaging with vascular structures, the decision to operate was made with the diagnosis of Alveolar echinococcosis.. Nonanatomical segmental right hepatectomy and total cyst excision operation was performed in our patient who was thought to have Alveolar echinococcosis based on clinical, serological and radiological findings. The patient, who had an uneventful postoperative period, was discharged on the 7th postoperative day with full recovery.

In cases of echinococcosis, the treatment is determined according to the type of the agent, the stage and localization of the lesion. Medical treatment, PAIR and surgery are the treatment options that can be applied. Total excision of the mass is recommended in cases of Alveolar echinococcosis.

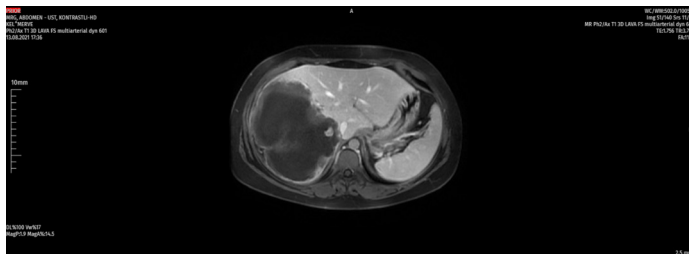**Keywords:** Alveolar Echinococcosis, Cystectomy, Hepatectomy

## INTRODUCTION

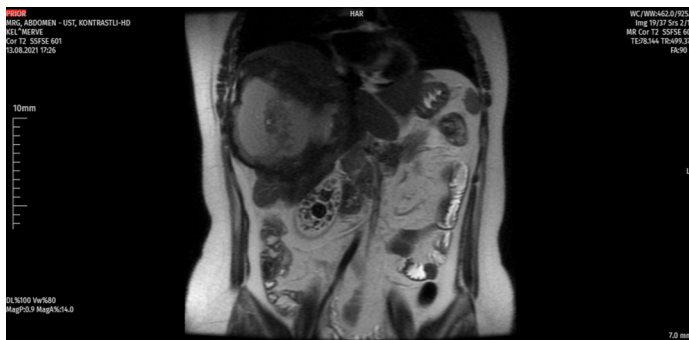
In this study, we aimed to present a case who presented with abdominal pain and was found to have an alveolar echinococcosis located in the right lobe of the liver with the operative and radiological images.

## CASE REPORT

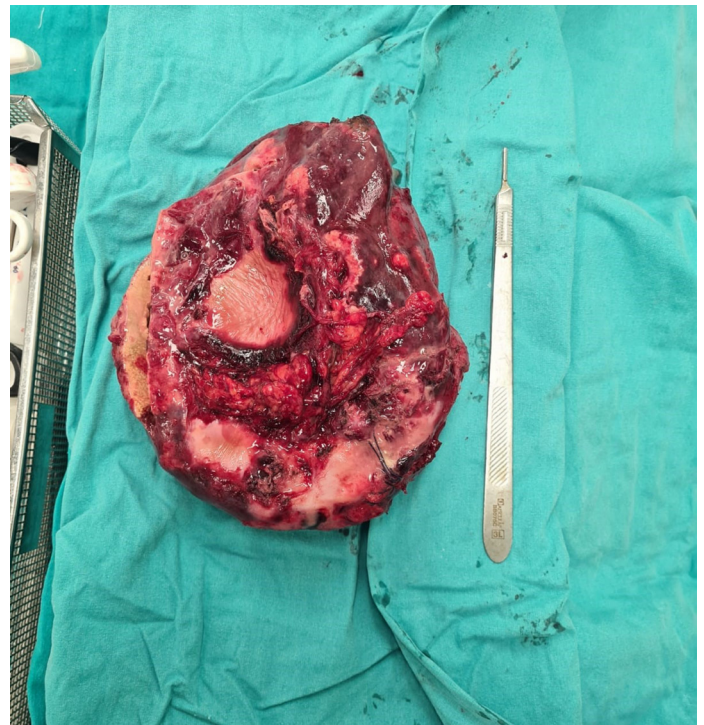The patient was a 31-years-old female. She admitted to hospital with intermittent abdominal pain. Abdominal ultrasonography revealed a cystic mass of approximately 17 cm in diameter in the right lobe of the liver. In laboratory examinations, the hydatid hemagglutination test was positive at a titer of 1/2560. Hematological and biochemical parameters were normal. MRI showed a 171\*125 mm sized, lobulated, locally calcified cystic mass in the right lobe of the liver (Figure 1) and multiple stones in the gallbladder (Figure 2). A diagnosis of alveolar echinococcosis was made based on clinical, serological and radiological findings. A diagnosis of alveolar echinococcosis was made in the presence of clinical, serological and radiological findings. The patient underwent surgery and right hepatectomy and cholecystectomy with total cyst excision were performed (Figure 3, 4). The histopathologic findings were found to be compatible with alveolar echinococcosis. The patient was discharged on the 7th postoperative day uneventfully.



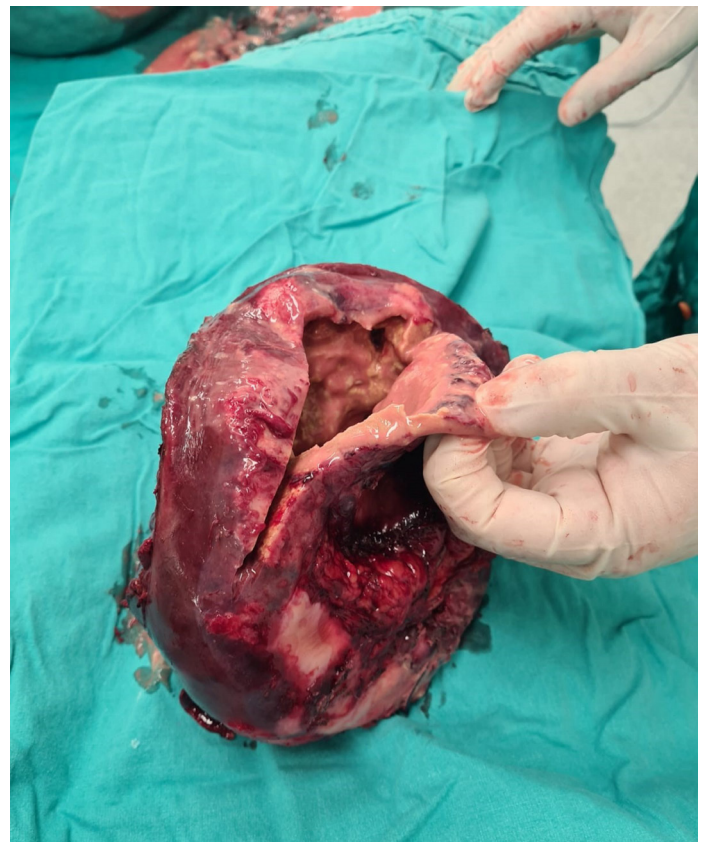
**Figure 1.** Appearance of a lobular, local calcified cystic mass in the right lobe of the liver in upper abdominal MRI



**Figure 2.** Upper abdomen MRI coronal section view of multiple gallbladder stones



**Figure 3.** View of right hepatectomy



**Figure 4.** View of total cystectomy material

## DISCUSSION

Considerable gaps of knowledge exist in pediatric Cystic echinococcosis (CE) has a worldwide distribution, while Alveolar echinococcosis (AE) is endemic in the Northern hemisphere, including North America and several Asian and European countries, like France, Germany and Austria (1). The disease is predominantly found in China and remains a major public health problem in Western China.

Recent studies in Europe and Asia have shown that the endemic area of *Echinococcus multilocularis* is larger than previously known and spread regionally from rural to urban areas (2).

Humans acquire the infection by accidental ingestion of eggs released into the environment by infected definitive hosts. A cyst located in the liver can cause symptoms when it reaches more than about 10 cm in diameter or when more than 70% of the organ volume is affected. Cystic mass can cause damage and compression to the hepatic and portal veins or bile ducts (3).

Alveolar echinococcosis causes liver tumors that result in infiltrative growth and distant metastases. Differential diagnosis of metastases from any other tumor should be made (4).

Clinically, AE behaves like a malignant tumor and the prognosis is generally poor. Alveolar echinococcosis is a serious disease with a greater than 90% mortality rate in untreated patients (5).

Hepatic resection is considered safe and the only curative treatment for AE when the lesion is able to be removed completely. It may be necessary to perform extrahepatic procedures like choledochojunostomy, diaphragm resection, adrenalectomy, nephrectomy, lung lobectomy, splenectomy to achieve radical resection, if there was adjacent organ invasion (6). Even if resection is noncurative for AE, good long-term survival and stabilization of the disease can be achieved with benzimidazole therapy if the lesion volume is reduced by 90% (7).

Studies on liver transplantation in patients with AE are limited, due to the excellent outcome of patients undergoing complete resection of the alveolar equinoccus and favorable results with conservative treatment. However, WHO recommends that transplantation may be considered in the presence of severe hepatic failure or

recurrent life-threatening cholangitis and in the absence of extrahepatic disease and if not suitable for radical liver resection (8).

## CONCLUSION

Surgery is the first choice for alveolar echinococcosis of the liver. Transplantation should also be considered as an option in selected cases.

**Competing interests:** The authors declare that they have no competing interest.

**Financial Disclosure:** There are no financial supports.

**Patient informed consent:** Patient consent was obtained for the publication of this article.

## REFERENCES

1. Nunnari G, Pinzone MR, Gruttadauria S, et al. Hepatic echinococcosis: Clinical and therapeutic aspects. *World J Gastroenterol.* 2012;18:1448-58.
2. Kern Peter, Clinical features and treatment of alveolar echinococcosis, *Current Opinion in Infectious Diseases:* October. 2010;23:505-12.
3. Wen H, Vuitton L, Tuxun T, et al. Echinococcosis: Advances in the 21st Century. *Clin Microbiol Rev.* 2019;32:e00075-18.
4. Tosun A, Tosun S. Sonographic evaluation of accessory spleen. *Göztepe Tip Dergisi.* 2011;26:54-7.
5. Kamiyama T. Recent advances in surgical strategies for alveolar echinococcosis of the liver. *Surg Today.* 2020;50:1360-67.
6. Shen S, Kong J, Zhao J, Wang W. Outcomes of different surgical resection techniques for end-stage hepatic alveolar echinococcosis with inferior vena cava invasion. *HPB (Oxford).* 2019;21:1219-29.
7. Kuscher S, Kronberger IE, Loizides A, et al. Exploring the limits of hepatic surgery for alveolar echinococcosis—10-years' experience in an endemic area of Austria. *Eur Surg.* 2019;51:189-96.
8. Salm LA, Lachenmayer A, Perrodin SF, et al. Surgical treatment strategies for hepatic alveolar echinococcosis. *Food Waterborne Parasitol.* 2019;15:e00050.